

---

**SURGICAL TECHNIQUE**


---

## CLINICAL EVALUATION OF LAPAROSCOPIC REPAIR OF LARGE HIATAL HERNIAS WITH TIMESH

ERIC J. HAZEBROEK, ADA NG, DAVID H. K. YONG, HAYLEY BERRY, STEVEN LEIBMAN AND GARETT S. SMITH

*Department of Surgery, Royal North Shore Hospital, Sydney, New South Wales, Australia*

The use of mesh for laparoscopic repair of large hiatal hernias may decrease recurrence rates in comparison with primary suture repair. The type of mesh material, as well as its size and shape, is still a matter of debate. The aim of this study was to evaluate a lightweight polypropylene mesh (TiMesh) repair of hiatal hernias, with particular reference to symptomatic relief, patient satisfaction and quality of life (QOL). From a prospectively maintained clinical database, 40 consecutive patients were identified who underwent elective laparoscopic hiatal hernia repair with TiMesh between November 2004 and December 2006. QOL and symptom analysis was carried out using Quality of Life in Reflux and Dyspepsia (QOLRAD) and dysphagia questionnaires preoperatively, and postoperatively after 6 weeks, 6 months, and 1 year. The mean age of the patient was 65.2 years (range: 40–93 years). Total complication rate was 7.5%; all complications were treated without residual disability. There was no 30-day mortality. Median hospital stay was 2.7 days (range 2–13 days). Completed questionnaires were obtained from 37 (92.5%) of 40 patients. After 1 year, more than 90% of patients were satisfied with their symptomatic outcome and regarded their surgery as successful. There was a significant improvement in QOL, measured with QOLRAD at all postoperative time-points ( $P < 0.001$ ). There was no difference between pre- and postoperative dysphagia scores. Laparoscopic repair of large hiatal hernias with TiMesh yields good symptomatic and clinical outcome. Further studies are needed to show whether the use of this lightweight polypropylene mesh is associated with a reduction in recurrence rates after hiatal hernia repair in the longer term.

**Key words:** endoscopy, hiatal hernia, laparoscopy, mesh, prosthesis.

Abbreviations: QOL, quality of life; QOLRAD, Quality of Life in Reflux and Dyspepsia; SIS, small intestinal submucosa.

### INTRODUCTION

It is generally acknowledged that primary repair of large hiatal defects results in higher than acceptable recurrence rates.<sup>1,2</sup> This has led to the increased use of fascial prostheses to augment the primary repair or create a tension-free repair.<sup>3–5</sup> Two prospective randomized studies have shown a significant reduction in recurrence rate with the use of mesh at short- to medium-term follow up.<sup>6,7</sup> However, the type of mesh material, as well as its size and shape, is still a matter of debate.<sup>8</sup> Numerous experimental studies have been carried out in search of the 'ideal mesh' for laparoscopic intraperitoneal use.<sup>9</sup> This ideal mesh should have optimal biocompatibility, that is good integration into surrounding tissues with minimal inflammatory reaction and no adhesion formation to intra-abdominal structures.

TiMesh (GfE Medizintechnik, Nuremberg, Germany) is a lightweight titanium-coated polypropylene mesh, weighing 35 g/m<sup>2</sup>. Several experimental data suggest that the lightweight and the large pores of the titanium-coated mesh are associated with a number of benefits, such as a more favourable foreign body reaction and less adhesion formation.<sup>10–12</sup>

**E. J. Hazebroek MD; A. Ng MB BS; D. H. K. Yong MB BS, FRACS; H. Berry; S. Leibman BSc(Med), MB BS, FRACS; G. S. Smith MS, FRACS.**

Correspondence: Dr Garrett S. Smith, Department of Upper Gastrointestinal Surgery, Level 2, Vindin House, Royal North Shore Hospital, St Leonards, NSW 2065, Australia.

Email: garetts@med.usyd.edu.au

Accepted for publication 11 April 2008.

The aim of this study was to critically evaluate TiMesh used for the laparoscopic repair of large hiatal defects, with particular reference to symptomatic relief, patient satisfaction and quality of life (QOL).

### MATERIALS AND METHODS

Data were collected prospectively on 40 consecutive patients undergoing laparoscopic repair of large hiatal defects using TiMesh from November 2004 until December 2006. Patients undergoing emergency surgery or surgery for recurrent hernia were excluded from this analysis. Length of hospital stay and intraoperative and postoperative complications were recorded.

Preoperative symptomatology and QOL were quantified using the Quality of Life in Reflux and Dyspepsia (QOLRAD) questionnaire.<sup>13,14</sup> QOLRAD is a condition-specific health-related QOL instrument, developed and tested for self-administration by patients with upper gastrointestinal symptoms. QOLRAD contains 25 items addressing concerns associated with gastro-oesophageal reflux disease symptoms. Items are rated on a seven-point scale; a higher score reflects improved QOL. QOLRAD has five subscales: emotional distress (six items), sleep disturbance (five items), food/drink problems (six items), physical/social functioning (five items) and vitality (three items). Subscale scores are obtained by summing all item responses and dividing by the number of items in the subscale.

According to Gill and Feinstein's criteria for assessment of QOL studies, patients were invited to supplement items in the questionnaire.<sup>15,16</sup> Furthermore, patients were asked to comment

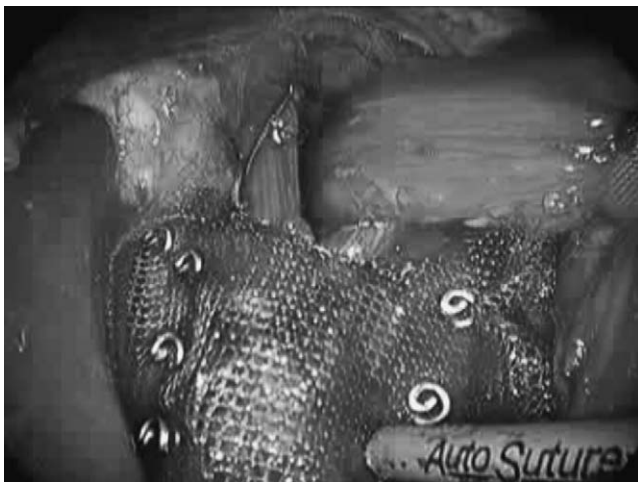on how successful they felt their surgery had been, whether their symptoms had improved or resolved and whether the operation had resulted in new persistent symptoms. Finally, they were asked whether they would undergo the operation again if they had the same problem.

Dysphagia scores were calculated for each patient pre- and postoperatively using a validated scoring method described by Dakkak and Bennett<sup>17</sup> Using this method, a patient with no dysphagia scores 45 and patient with profound dysphagia scores 0.

Preoperative questionnaires were administered during office visits. Patients were allowed to fill out the questionnaires at home and were requested to return the forms by mail before their surgery. Postoperatively, QOL instruments were applied at 6 weeks, 6 months and 1 year. If necessary, patients were contacted by telephone to remind them to send the questionnaire. Patient interviews and collection of QOL instruments were carried out by a data manager independent of surgical follow up. QOLRAD scores are presented as median scores and analysed nonparametrically using the Mann–Whitney *U*-test. A *P*-value of < 0.05 was considered statistically significant.

### Operative technique

All operations were carried out by the senior authors (G. S. S. and S. L.) or trainees under their supervision. Surgery was carried out with the patient in the modified lithotomy position, with the operating surgeon between the patient's legs and the assistant to the patient's left. The left lateral hepatic segments were retracted using a fixed uniplanar hook retractor (Nathanson's Liver Retraction System; Cook Medical Technology, Brisbane, Australia). The hernia sac was dissected from its mediastinal attachments using ultrasonic shears (Ultracision Coagulating Shears; Ethicon Endosurgery, Cincinnati, OH, USA). A nylon sling was placed around the cardio-oesophageal junction. The hernia sac was debulked taking care to avoid vascular or vagal injury. After both crural pillars were approximated with 0 Ethibond sutures (Ethicon Endosurgery), the TiMesh prosthesis was placed on the crural repair and fixed to the crural muscle and diaphragm with laparoscopic helical screws (ProTack 5 mm, Autosuture; Tyco Healthcare, Princeton, NJ, USA) (Fig. 1). A dorsal 270° fundoplication was carried out



**Fig. 1.** Operative view of TiMesh repair. After primary crural closure, the hiatoplasty is reinforced with TiMesh. The mesh is fixed to the diaphragmatic crura with titanium helical screws.

routinely. Fundoplication and crural closure were calibrated over a 56-Fr Maloney bougie. Routine postoperative fluoroscopy was carried out. Clear fluids were given orally after fluoroscopic examination.

### RESULTS

There were 29 women and 11 men in this series. The age of the patients ranged from 40 to 93 years (mean 65.2 years). Mean ASA (American Society of Anesthesiologists) score was 2.7 (range 1–3). Mean duration of symptoms was 7.9 years (range 1–20 years). Heartburn and chest pain were present in the majority of patients before surgery (62.5%) (Table 1). Other common symptoms included regurgitation, dysphagia and respiratory compromise (defined by symptoms of shortness of breath, cough or asthma).

All procedures were completed laparoscopically, and there was no in-hospital or 30-day mortality. The median postoperative stay was 2.7 days (2–13 days). There was early reoperation in one patient who developed dysphagia and retrosternal pain. Although a computed tomography scan did not show signs of perforation, gastrografin swallow was suggestive of a small leak. Simultaneous laparoscopic and endoscopic evaluation was carried out on the 10th postoperative day. No perforation was visualized, and therefore, it was assumed that a microperforation had occurred secondary to tension of one of the fundoplication sutures. A removable polyester stent was inserted, and further postoperative course was uneventful in this patient. There were two other postoperative complications: one pleural effusion requiring drainage and one atrial arrhythmia requiring treatment.

Data obtained from barium studies and endoscopies, carried out in patients with a minimum postoperative follow-up period of 2 years, were available in 18 patients of this study cohort (45%). There were no complications identified at endoscopy, in particular no intraluminal mesh erosion or stricture. Polyester sutures were visible in one patient where the fundoplication had been sutured to the crural repair. There was no mesh visible in this case. The suture material was removed endoscopically. Postoperative barium studies showed a small (2 cm) hernia in one patient, which was asymptomatic.

### Quality of life and patient satisfaction

Completed pre- and postoperative questionnaires were obtained from 37 (92.5%) of 40 patients. Incomplete follow up occurred because of the following reasons: two patients expressed to be daunted by the size of the questionnaires and one patient who was dissatisfied with her symptomatic outcome declined to complete questionnaires.

**Table 1.** Pre- and postoperative incidence of symptoms (*n* and %)

Symptom	Preoperative ( <i>n</i> = 40), <i>n</i> (%)	Postoperative ( <i>n</i> = 37), <i>n</i> (%)	New symptoms ( <i>n</i> = 37), <i>n</i> (%)
Heartburn	25 (62.5)	7 (18.9)	0 (0)
Regurgitation	21 (52.5)	4 (10.8)	0 (0)
Chest pain	25 (62.5)	6 (15.7)	2 (5.4)
Respiratory compromise	20 (50)	7 (18.9)	0 (0)
Dysphagia	17 (42.5)	8 (21.6)	3 (8.1)
Anaemia	7 (17.5)	1 (2.7)	0 (0)
Gas bloat	16 (40)	5 (13.5)	7 (18.9)

After laparoscopic hiatal hernia repair, significant improvements in QOLRAD scores were documented for each of the items (emotional, sleep, food, physical and vitality) in the questionnaire at all postoperative time-points ( $P < 0.001$ ) (Fig. 2).

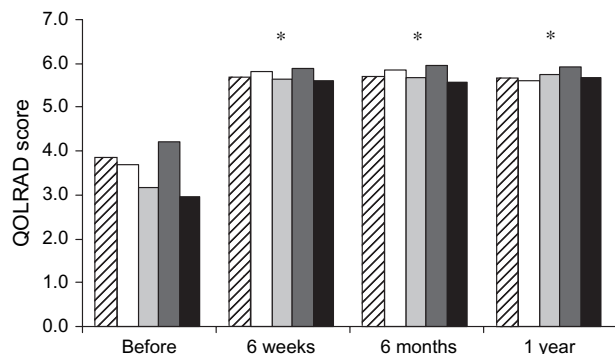
One year postoperatively, 38 (95%) of 40 patients documented that their symptoms had improved and considered their surgery successful. In 14 (46.7%) of 30 patients, symptoms had completely resolved. Twelve (32.4%) patients mentioned that the operation had resulted in new symptoms, with the majority of them having complaints of gas bloating (seven new cases) (Table 1).

None of the patients reported a worsening in dysphagia postoperatively either on direct questioning or on scoring. Preoperatively, mean dysphagia score was 35.2. Postoperative dysphagia scores were 40.9, 40.8 and 41.8 at 6 weeks, 6 months and 1 year, respectively. Of the patients with dysphagia, more than 90% documented that they could eat a normal range of foods without difficulty. None of the patients in this cohort underwent endoscopic dilatation for postoperative dysphagia. Thirty-seven (92.5%) of 40 patients documented that they would undergo the operation again if they had the same problem.

## DISCUSSION

Paraoesophageal hernias occur when there is herniation of the fundus of the stomach through a dilated hiatal aperture. This may occur in association with intramediastinal dislocation of the lower oesophageal sphincter in which case the term mixed hiatal hernia is often used. These hernias tend to occur in elderly women, although adults of any age and sex may be affected. Symptoms are due to the mechanical effect of the hernia and are therefore often resistant to pharmacological treatment. In contrast to the more common sliding hiatal hernias, paraoesophageal hiatal hernias can lead to acute gastric obstruction and bleeding from gastric volvulus or infarction, which warrants a surgical approach.

Large hiatal hernias present a difficult management problem. Operative repair can be technically challenging, but it is also generally acknowledged that primary repair of large hiatal defects results in higher than acceptable recurrence rates.<sup>1,2</sup> This has led to the increased use of fascial prostheses to augment the primary repair or create a tension-free repair,<sup>3,5</sup> given the fact that the use



**Fig. 2.** Pre- and postoperative Quality of Life in Reflux and Dyspepsia (QOLRAD) scores, specified by item in the questionnaire (▨ emotional, □ sleep, ◻ food, ◼ physical and ◼ vitality). After laparoscopic paraoesophageal hernia repair, significant improvements in QOLRAD scores were documented at short- and long-term follow up for each specific item in the questionnaire (\* $P < 0.001$ ).

of mesh in other hernias (inguinal and incisional) has been shown to reduce recurrence rates.<sup>18,19</sup> Two prospective randomized studies have shown a significant reduction in recurrence rate after laparoscopic repair of hiatal hernias with the use of mesh at short- to medium-term follow up.<sup>6,7</sup>

However, the use of mesh at the diaphragmatic hiatus remains a point of controversy as serious complications because mesh migration and erosion have been described.<sup>20</sup> In addition, the type of mesh material, as well as the size and shape of the mesh repair, is a matter of ongoing debate.<sup>8</sup> Numerous experimental studies have been carried out in search of the ideal mesh for laparoscopic intraperitoneal use.<sup>9</sup> This ideal mesh should be inexpensive and malleable and have optimal biocompatibility, that is good integration into surrounding tissues with minimal inflammatory reaction and no adhesion formation to intra-abdominal structures. The most commonly used synthetic meshes are polypropylene and polytetrafluoroethylene (PTFE). Most experimental studies and theoretical considerations argue for using PTFE meshes because they may prevent (or at least reduce) adhesion formation between the mesh and the intra-abdominal viscera.<sup>9</sup> Although it is reasonable to assume that of these two materials, PTFE would be less likely to result in morbidity when used for reinforcement of the crural repair, there are no clinical data to support this. It has been suggested that the use of biomaterial mesh may be a safe and better alternative to the use of synthetic mesh, in order to avoid mesh-related oesophageal or gastric injury.<sup>20</sup> These biological meshes purport to act as an extracellular matrix scaffold to augment native tissue healing and regeneration. Because they are pliable and temporary, they should not have the risks inherent to synthetic mesh. In a prospective randomized trial using such biomaterial (porcine submucosa (SIS); Surgisis; Cook Biotech, West Lafayette, IN, USA), Oelschlager *et al.* showed that SIS was associated with a significantly lower recurrence rate compared with primary repair (9 vs 24%, respectively) at 6-month follow up, determined by radiological assessment.<sup>7</sup>

Several studies evaluating prosthetic mesh have shown that material reduction improves tissue integration by reducing inflammation and fibrosis.<sup>10,21,22</sup> Furthermore, it is suggested that the lightweight and the large pores of the titanium-coated polypropylene mesh are associated with a number of benefits. In a study comparing the biocompatibility of various polypropylene meshes and their handling properties during endoscopic extraperitoneal hernia patch plasty, Scheidbach *et al.* showed that the reduction of material in lightweight polypropylene mesh was characterized by a more favourable foreign body reaction, with the titanium coating of TiMesh providing additional advantages in terms of its biocompatibility.<sup>11</sup> In a recent experimental study by Schug-Pass *et al.*,<sup>12</sup> the use of titanium-coated polypropylene mesh showed characteristics comparable to those of DualMesh (ePTFE) in terms of adhesions and proved to be superior in terms of mesh shrinkage.

At present, there are no clinical studies available on the use of TiMesh for laparoscopic repair of large hiatal hernias. This study therefore currently represents the most thorough evaluation of this specific mesh type regarding symptomatic outcome after hiatal hernia repair. It has been described that some patients with prosthetic hiatal closure may suffer from prolonged postoperative symptoms such as dysphagia or chest pain; therefore, we assessed postoperative symptoms and dysphagia in all patients who underwent laparoscopic repair of large hiatal defects with TiMesh.<sup>8</sup> After 1 year, there was a significant improvement in symptomatic outcome in the overwhelming majority of patients. None of the

patients reported a worsening in dysphagia postoperatively either on direct questioning or on scoring.

Although these short- to mid-term results based on symptom assessment are promising, the design and methodology of this study do not allow us to determine whether the use of TiMesh decreases recurrence rates after hiatal hernia repair. To determine the true recurrence rate after laparoscopic repair of large hiatal hernias, objective anatomical studies are required.<sup>1</sup> At our institution, all patients having laparoscopic repair of a large hiatal hernia are routinely assessed for hernia recurrence by endoscopy and barium studies after 2 years. Of the patients described in this study cohort who have a 2-year follow-up period, postoperative barium studies showed a small (2 cm) hernia in only one patient, which was asymptomatic.

The search for the ideal prosthesis for laparoscopic repair of large hiatal defects is ongoing. The effect on repair durability and risk of complications associated with factors such as prosthetic materials, configuration of grafts and the mode of fixation will require thorough evaluation.

In conclusion, the results from this study show that laparoscopic reinforcement of primary hiatal closure with TiMesh leads to a durable repair in patients with large hiatal hernias and is associated with a significant improvement in QOL without increasing the risk of postoperative dysphagia. Further studies are needed to show whether reinforcement of the hiatal repair with this lightweight polypropylene mesh is also associated with a reduction in recurrence rates in the longer term.

## REFERENCES

1. Aly A, Munt J, Jamieson GG, Ludemann R, Devitt PG, Watson DI. Laparoscopic repair of large hiatal hernias. *Br. J. Surg.* 2005; **92**: 648–53.
2. Smith G, Isaacson J, Draganic B, Baladas H, Falk G. Symptomatic and radiological follow up after para-oesophageal hernia repair. *Dis. Esophagus* 2004; **17**: 279–84.
3. Basso N, De Leo A, Genco A *et al.* 360 degrees laparoscopic fundoplication with tension-free hiatoplasty in the treatment of symptomatic gastroesophageal reflux disease. *Surg. Endosc.* 2000; **14**: 164–9.
4. Behrns KE, Schlinkert RT. Laparoscopic management of paraesophageal hernia: early results. *J. Laparoendosc. Surg.* 1996; **6**: 311–17.
5. Carlson MA, Condon RE, Ludwig KA, Schulte WJ. Management of intrathoracic stomach with polypropylene mesh prosthesis reinforced transabdominal hiatus hernia repair. *J. Am. Coll. Surg.* 1998; **187**: 227–30.
6. Frantzides C, Madan A, Carlson M, Stavropoulos G. A prospective, randomized trial of laparoscopic polytetrafluoroethylene (PTFE) patch repair vs simple cruroplasty for large hiatal hernia. *Arch. Surg.* 2002; **137**: 649–52.
7. Oelschlager BK, Pellegrini CA, Hunter J *et al.* Biologic prosthesis reduces recurrence after laparoscopic paraesophageal hernia repair: a multicenter, prospective, randomized trial. *Ann. Surg.* 2006; **244**: 481–90.
8. Granderath F, Carlson M, Champion JK *et al.* Prosthetic closure of the esophageal hiatus in large hiatal hernia repair and laparoscopic antireflux surgery. *Surg. Endosc.* 2006; **20**: 367–79.
9. Eriksen JR, Gogenur I, Rosenberg J. Choice of mesh for laparoscopic ventral hernia repair. *Hernia* 2007; **11**: 481–92.
10. Klosterhalfen B, Junge K, Klinge U. The lightweight and large porous mesh concept for hernia repair. *Expert Rev. Med. Devices* 2005; **2**: 103–17.
11. Scheidbach H, Tamme C, Tannapfel A, Lippert H, Kockerling F. In vivo studies comparing the biocompatibility of various polypropylene meshes and their handling properties during endoscopic total extraperitoneal (TEP) patchplasty: an experimental study in pigs. *Surg. Endosc.* 2004; **18**: 211–20.
12. Schug-Pass C, Tamme C, Tannapfel A, Kockerling F. A lightweight polypropylene mesh (TiMesh) for laparoscopic intraperitoneal repair of abdominal wall hernias: comparison of biocompatibility with the DualMesh in an experimental study using the porcine model. *Surg. Endosc.* 2006; **20**: 402–9.
13. Wiklund I, Junghard O, Grace E *et al.* Quality of life in reflux and dyspepsia patients. Psychometric documentation of a new disease-specific questionnaire (QOLRAD). *Eur. J. Surg.* 1998; **164** (Suppl. 583): 41–9.
14. Kulich KR, Wiklund I, Junghard O. Factor structure of the Quality of Life in Reflux and Dyspepsia (QOLRAD) questionnaire evaluated in patients with heartburn predominant reflux disease. *Qual. Life Res.* 2003; **12**: 699–708.
15. Gill TM, Feinstein AR. A critical appraisal of the quality of quality-of-life measurements. *JAMA* 1994; **272**: 619–26.
16. Velanovich V. The quality of quality of life studies in general surgical journals. *J. Am. Coll. Surg.* 2001; **193**: 288–96.
17. Dakkak M, Bennett JR. A new dysphagia score with objective validation. *J. Clin. Gastroenterol.* 1992; **14**: 99–100.
18. Shulman AG, Amid PK, Lichtenstein IL. The safety of mesh repair for primary inguinal hernias: results of 3,019 operations from five diverse surgical sources. *Am. Surg.* 1992; **58**: 255–7.
19. Luijendijk RW, Hop WC, van den Tol MP *et al.* A comparison of suture repair with mesh repair for incisional hernia. *N. Engl. J. Med.* 2000; **343**: 392–8.
20. Tatum RP, Shalhub S, Oelschlager BK, Pellegrini CA. Complications of PTFE mesh at the diaphragmatic hiatus. *J. Gastrointest. Surg.* 2008; **12**: 953–7.
21. Klinge U, Klosterhalfen B, Birkenhauer V, Junge K, Conze J, Schumpelick V. Impact of polymer pore size on the interface scar formation in a rat model. *J. Surg. Res.* 2002; **103**: 208–14.
22. Conze J, Rosch R, Klinge U *et al.* Polypropylene in the intra-abdominal position: influence of pore size and surface area. *Hernia* 2004; **8**: 365–72.

Copyright of ANZ Journal of Surgery is the property of Blackwell Publishing Limited and its content may not be copied or emailed to multiple sites or posted to a listserv without the copyright holder's express written permission. However, users may print, download, or email articles for individual use.